

FERTILITY PRESERVATION CASE STUDIES

Serena Dovey, MD
Director of Fertility Preservation
at the
University of Colorado

CASE 1

Holly is a 14 year old female referred initially in 2015 for fertility counseling.

She was diagnosed with Stage IV Neuroblastoma at the age of 5.

She underwent induction phase chemotherapy with Cyclophosphamide / doxorubicin / vincristine x 4 cycles plus Cisplatin / Etoposide x 2 cycles, followed by surgical resection.

Holly then underwent autologous stem cell transplant – preparative therapy included Melphalan, Carboplatin and Etoposide

Following stem cell transplant, Holly had abdominal radiation (total 2160 cGy)

In remission x 7 years

CASE 1

Pt underwent menarche spontaneously at age 13

Periods fairly regular but will occasionally skip.

Interested in having children in the future.

CASE 1

Initial fertility assessment:

- 2014
 - FSH 15.5 / LH 9 / E2 41
 - AMH undetectable.
- 2015
 - FSH 2.6 / LH 0.3 / E2 55
 - AMH 0.1
 - Pelvic US: Normal uterus; large simple cyst on left. AFC 1-2.

How would you counsel this patient about future fertility?

CASE 1

Holly returns at age 15; repeat assessment of ovarian reserve

- 2017
 - FSH 12 / LH 4.6 / E2 32
 - AMH 0.3
 - Pelvic US: AV uterus; AFC 6 (all on left)

How should patient be counseled now? Should egg-banking be offered?

If banking offered, would you recommend having a certain # of follicles develop to proceed to retrieval?

CASE 1

Holly desired to proceed with egg-banking

She underwent uncomplicated stimulation and egg-retrieval. Three follicles developed, 3 MII eggs retrieved and cryopreserved.

How do you counsel her regarding chances for pregnancy?

CASE 1

Holly returns a year later. She continues to have fairly regular menstrual cycles.

Interested in undergoing another egg-banking cycle to increase odds for pregnancy with cryopreserved eggs.

Assessment of ovarian reserve:

- 2018:
 - FSH 7.8 / LH 4.6 / E2 29
 - AMH 0.35
 - Pelvic US: AFC ~6

Currently in process of undergoing a second banking cycle.

CASE 1

How many eggs / cycles would you recommend for Holly?

CASE 1 (PART 2)

Annie is a 12 year old female with a history of an allogenic matched sibling cord blood transplant for recurrent promyelocytic leukemia (conditioning with multi-agent chemotherapy plus TBI); in remission since 2011.

Had spontaneous menarche last year; reports fairly regular menses

Assessment of ovarian reserve:

- FSH 7.4 / LH 5.8 / E2 31
- AMH 0.1
- Pelvic US (abdominal) – AFC ? 5

Would you counsel this patient any differently?

CASE 2

Jen is a 28 year old G0 who was diagnosed with Stage IB low grade serous ovarian cancer 3 years ago.

At that time, she underwent left oophorectomy, right ovarian cystectomy and fertility-sparing staging.

Not referred for fertility counseling at that time.

Jen now referred given new complex mass within right ovary with little normal ovarian tissue seen.

Jen reports regular menstrual cycles.

CASE 2

Jen highly desires pregnancy in the future. Currently single has never TTC

Testing demonstrates:

- FSH 9 / E2 28
- AMH 1.5
- Pelvic US: AFC unable to assess given large cystic mass within ovary

GYN/ONC planning repeat surgery, with possible RSO.

How would you counsel her regarding options?

CASE 2

- Fatemi et al. Ex-vivo oocyte retrieval for fertility preservation. *Fertil Steril* 2011.
 - 27 year old with history of borderline serous adenocarcinoma treated with LSO and fertility-sparing staging. Represented 2 years later with complex cyst on right ovary.
 - Patient underwent ovarian stimulation and laparotomy performed 36 hours after trigger.
 - Once ovary was removed, placed in stainless steel bowl and egg retrieval performed with traditional egg retrieval single lumen needle.
 - 13 eggs retrieved, and 11 were MII

CASE 2

Bocca et al. JARG 2011

- Similar case; authors report removal of stimulated ovary laparoscopically in atraumatic fashion with endocatch bag.
- 22 eggs retrieved, 14 MII frozen.

De la Blanca et al. JRI 2018

- Ex-vivo egg retrieval performed using standard ultrasound-guided procedure to improve imaging

CASE 2

Ex-vivo egg retrieval offered to patient and planned with GYN ONC

- Issues discussed:
 - Timing of GYN ONC performing laparotomy in conjunction with ovarian stimulation
 - Coordination with IVF lab
- Pt ultimately opted not to proceed 😞



Fertility Preservation

Emelia Bachman, MD
Reproductive Associates of Delaware

Clinical Cases in Oncofertility
November 15, 2018

Case 1: Aplastic Anemia

- EE is a 17 year-old G0 with recently diagnosed aplastic anemia presented for fertility preservation consult.
- Presented to pediatrician with fatigue and bruising
- On ocp due to heavy menstrual bleeding for 8 months
- CBC demonstrated pancytopenia
- Bone marrow biopsy confirmed diagnosis
- Bone marrow transplantation planned

Exam and studies

- BMI 25 kg/m²
- Abdominal ultrasound: Uterus and ovaries wnl.
AFC 20
- Labs:
 - AMH 4.8 ng/mL
 - FSH 0.4 IU/L
 - E2 <10 pg/mL
 - LH 1.5 IU/L
 - P4 0.41 ng/mL

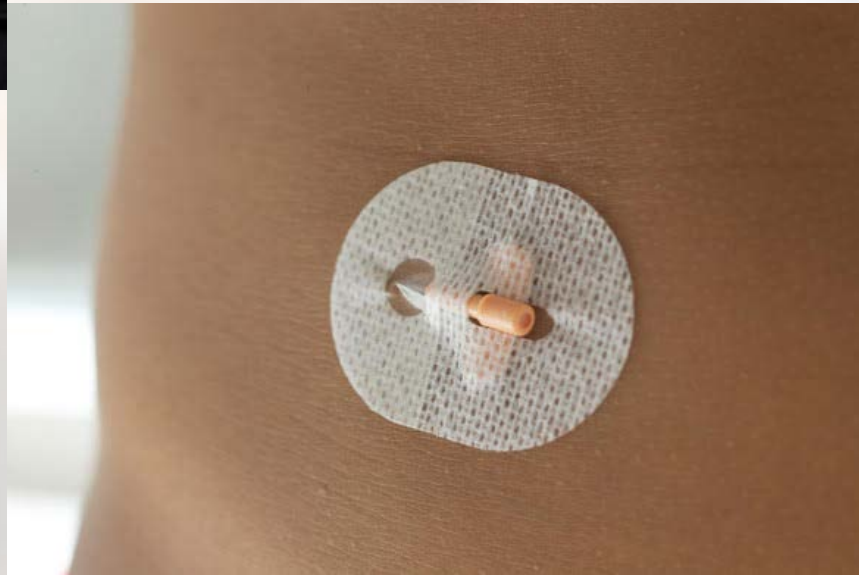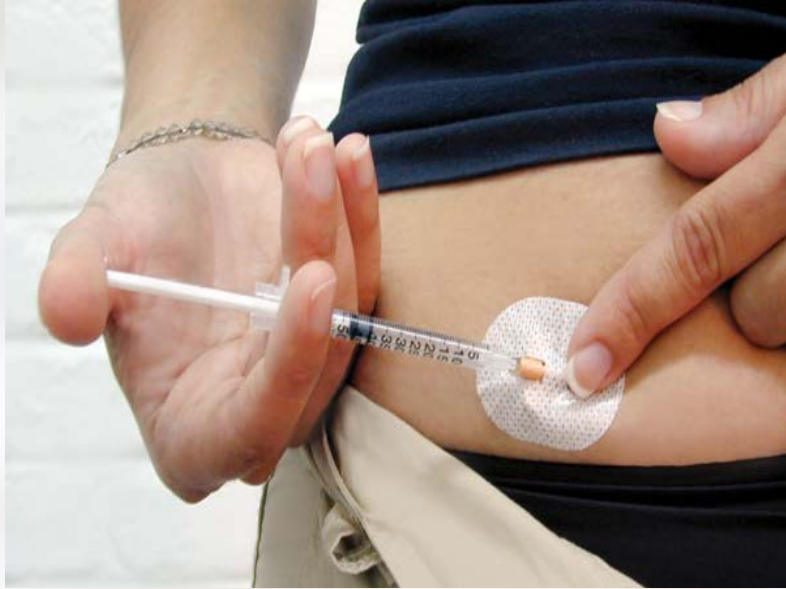Ovarian stimulation and results

- Protocol: clomiphene citrate/rFSH 300
- 24 follicles total, 12 follicles > 18 mm
- Maximum estradiol 4835 pg/mL
- Triggered with lupron TD 13
- Pre-operative transfusion of blood and platelets
- 16 oocytes retrieved
- 10 M2, 1 M1, 5 atretic
- 10 M2 oocytes cryopreserved

EE: Special Considerations

- Psychological aspects of adolescent undergoing ovarian hyperstimulation
 - Social work and psychology at Nemours
 - Consults with both physician, nurse and coordinator
 - Process of ovarian hyperstimulation
 - Informed consent
 - Medication teaching
 - Indwelling subcutaneous catheter
 - Abdominal ultrasounds for monitoring
 - Labs drawn from PICC line
 - Admission post retrieval for pain control and monitoring

Indwelling subcutaneous catheter



EE: Special Considerations

- Multidisciplinary collaboration
 - Discussion with hematology team regarding timeline of treatment and safety of oocyte hyperstimulation and retrieval
 - Monitoring of blood indices and appropriate transfusion when necessary.
 - Goal prior to retrieval Hg >10 and platelets >50K
 - Placement of indwelling subcutaneous catheter for ease of medication administration
 - Blood draws from PICC line to avoid multiple blood draws in patient
 - Admission post-op for monitoring and pain control

Case 2: Cervical cancer

- KW is a 30 year-old G0 with Stage IIB adenocarcinoma of cervix
- Pelvic radiation and chemotherapy planned
- BMI 20
- Cycle day 14 of menses at initial consultation
- Ultrasound: 21x32 mm cervical mass.
 - Right ovary with dominant follicle. AFC 18
- Labs
 - AMH 3.1 ng/mL
 - E2 284 pg/mL
 - FSH 2.57 mIU/mL
 - LH 9.4 mIU/mL
 - P4 0.51 ng/mL

Stimulation

- Luteal phase start
 - E2 90 pg/mL, LH 14 mIU/mL, P4 6.4 ng/mL, FSH 5 mIU/mL
 - US: Corpus luteum present 16x12mm
- Antagonist/Menopur 300 → decreased to 225 TD 9
- 24 follicles, 15 > 18 mm
- Maximum estradiol 5007 pg/mL
- Trigger with lupron on TD 10
- Abdominal retrieval
- 21 oocytes
 - 16 M2, 5 GV
- 4 M2 oocytes cryopreserved
- 12 M2 fertilized → 11 2pn → 7 day 5 blastocysts cryopreserved
- FDA labs/exam/questionnaire completed for both partners

KW: Special Considerations

- Transvaginal vs. transabdominal retrieval
- Technique of transabdominal retrieval
- FDA criteria for future gestational carrier

Transabdominal retrieval

- Indications
 - Cervical or vaginal mass
 - Vaginal agenesis
 - Ovaries not clearly visualized transvaginally
 - Fibroids, pelvic adhesions, body habitus
- Procedure
 - Dorsal supine vs. dorsal lithotomy position
 - IV antibiotics
 - Prep abdominal wall
 - Use sterile standard 17-gauge retrieval needle
 - Sterilely draped vaginal or abdominal probe with or without needle guide
- Issues
 - Lower oocyte yield
 - Technically challenging
 - Limited experience

Transabdominal retrieval

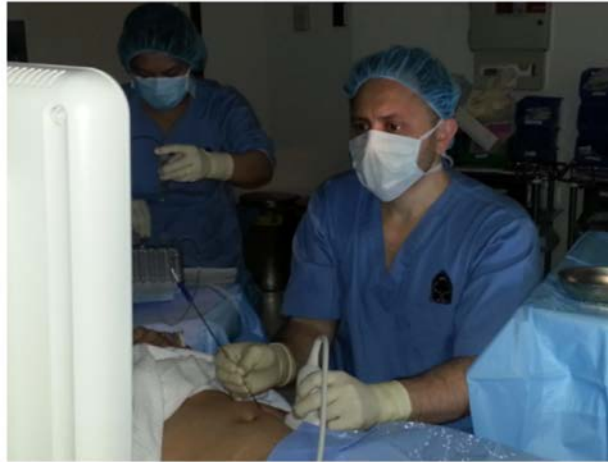- 69 cases
 - 57 abdominal only, 12 both abdominal and vaginal retrieval
- Lower number of oocytes retrieved compared to vaginal retrieval
- May require multiple puncture sites
- One complication in group

TABLE 2			
In vitro fertilization outcomes compared between transabdominal and transvaginal follicular aspiration groups.			
Variable	Transabdominal^a	Transvaginal	P value
No. of oocytes			
Total	11.9 ± 0.8 ^b	14.1 ± 1.0 ^b	.008 ^c
Mature	9.2 ± 0.9	7.3 ± 0.9	.14
Degenerated	0.19 ± 0.08	0.38 ± 0.09	.04
Broken zona pellucida	0.09 ± 0.05	0.07 ± 0.04	.94
Normal fertilization	6.7 ± 0.6	7.7 ± 0.7	.18
Fertilization rate (%)	63.4 ± 3.1	67.1 ± 2.7	.35
No. of embryos available for transfer	6.4 ± 0.6	7.7 ± 0.7	.08
Average no. of cells per embryo	6.5 ± 0.2	6.7 ± 0.2	.96
Average fragmentation score	1.6 ± 0.1	1.9 ± 0.1	.13
Pregnancy rate (%)			
Clinical	27.5 ^d	36.2 ^d	.36 ^e
Ongoing	21.7 ^d	26.1 ^d	.69 ^e

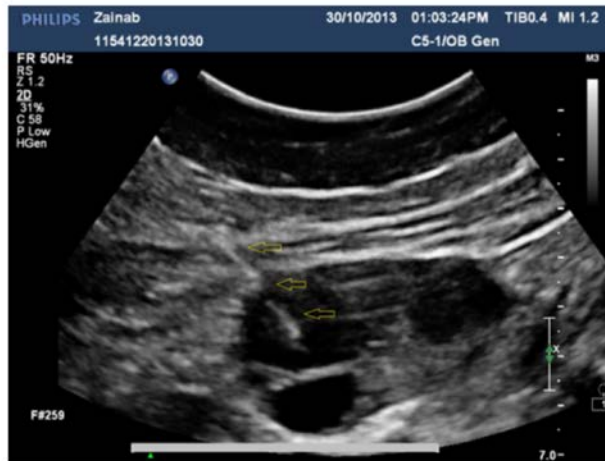Barton et al, Fertility and Sterility 2011

Transabdominal retrieval

A



B



ASRM Guidelines 2017

Recommendations for practices utilizing gestational carriers: a committee opinion

Practice Committee of the American Society for Reproductive Medicine and Practice Committee of the Society for Assisted Reproductive Technology

American Society for Reproductive Medicine, Birmingham, Alabama

- Donor screening questionnaire
- Physical examination
- FDA labs
 - Negative results documented within
 - 30 days of oocyte retrieval
 - 7 days of sperm collection

Discussion and Questions





Clinical Cases in Oncofertility

Laxmi A Kondapalli, MD MSCE
Colorado Center for Reproductive Medicine

Oncofertility Consortium Annual Meeting
November 15, 2018 ♦ Chicago, IL



Patient LM: initial presentation

- ❖ Diagnosed with Turner syndrome at age 13
- ❖ Presented to CHC with short stature
- ❖ Received growth hormone to achieve current height 5'5"
- ❖ Karyotype: 45XO, 46XX

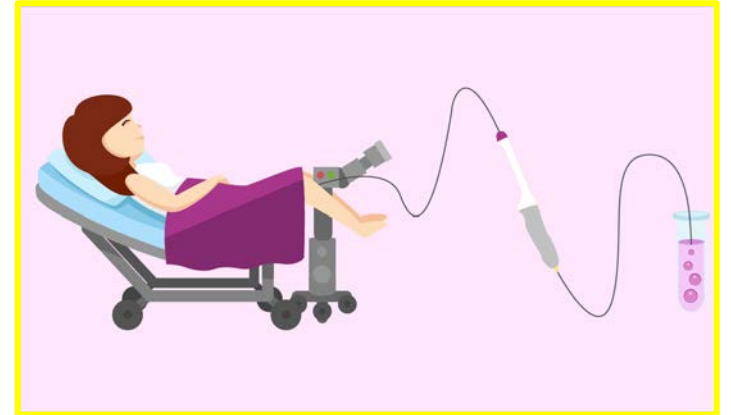
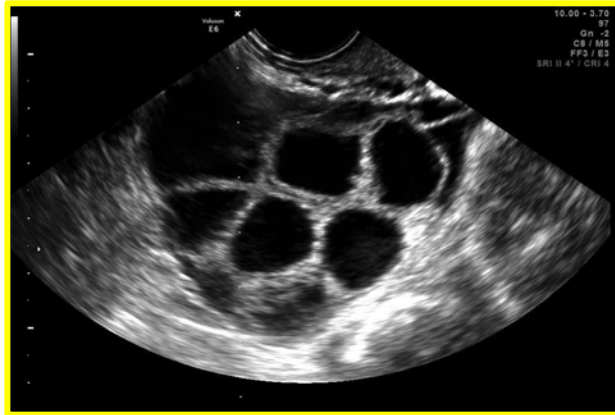
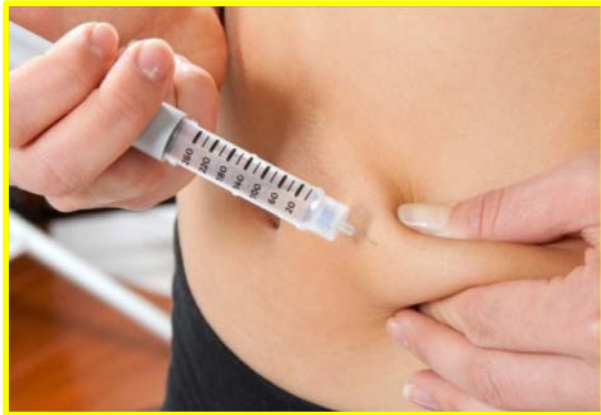```
Karyotype
45,X[7]/46,XX[43]
Karyotype
Abnormal karyotype, female
Specimen type
Peripheral Blood
INDICATIONS FOR STUDY
Underweight / Short stature
Metaphases counted, blood tissue, molecular genetics, qual
50
```

Patient LM: current presentation

- ❖ History of delayed puberty
 - ❖ Achieved spontaneous pubertal milestones
 - ❖ Menarche at age 16
 - ❖ Cyclic menses every 30 days
- ❖ PMH: history of aortic stenosis → repaired as infant
- ❖ Meds: lisinopril

Patient LM: fertility preservation consultation

- ❖ Presented at 18 years with her parents for FP consult
- ❖ Desired future biological children
- ❖ College student → winter break
- ❖ Long discussion about process of egg banking

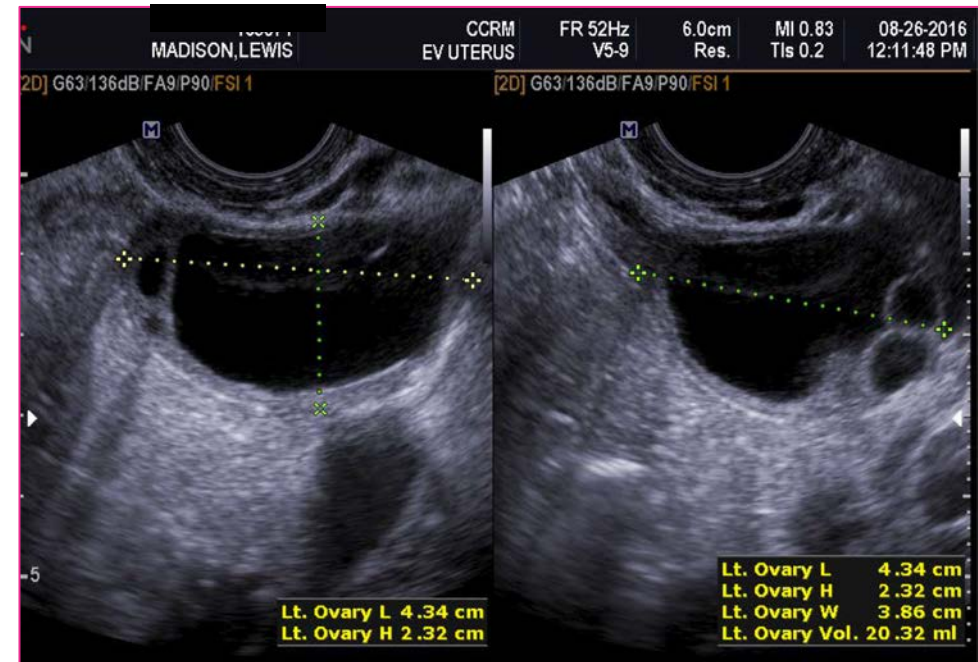
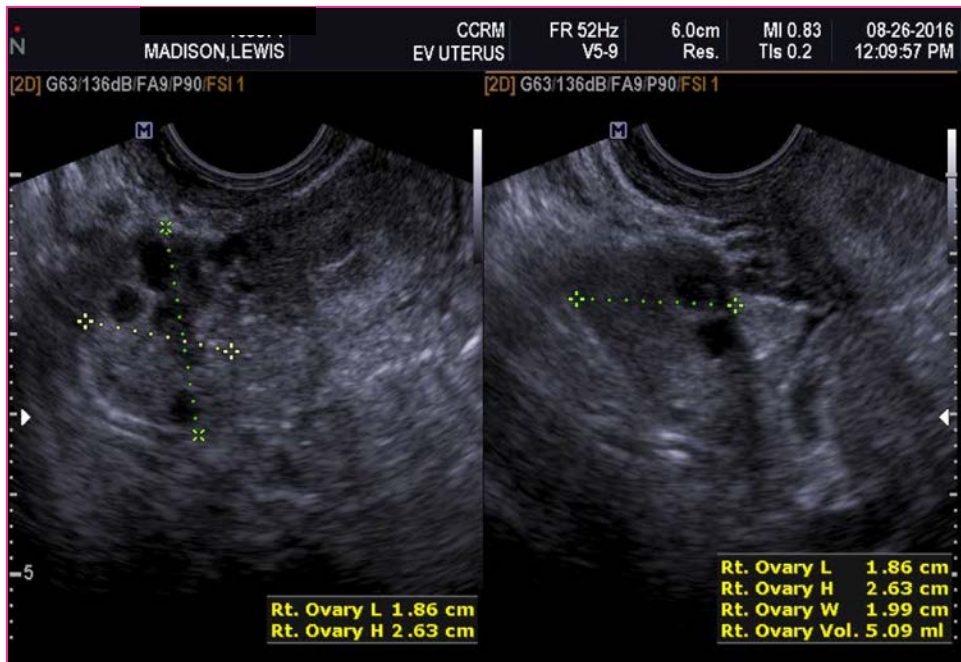


Patient LM: special considerations

- ❖ Spontaneous thelarche, adrenarche and menarche
- ❖ Current cyclic menses
- ❖ Ovarian reserve?
- ❖ History of aortic stenosis s/p repair
- ❖ Use of comprehensive chromosomal screening
- ❖ Future pregnancy and use of gestational carrier

Patient LM: ovarian reserve & prescreening

- ❖ AMH: 0.7
- ❖ Antral follicle count: 12
- ❖ Cardiac clearance



Patient LM: stimulation

- ❖ Random start antagonist protocol
 - ❖ 11 days of stimulation
 - ❖ Max E2 = 2592 pg/ml
 - ❖ Dual trigger with GnRHa and hcg
 - ❖ FDA criteria for future GC
 - ❖ IV antibiotics
- ❖ Cycle outcome:
 - ❖ 11 oocytes retrieved
 - ❖ 8 MII + 2MI → MII (IVM)
 - ❖ *10 oocytes vitrified*

PM MED 1			GonF 300	GonF 300
PM MED 2				
PM MED 3				
AM MED 1			MEN 150	MEN 150
AM MED 2				
AM MED 3				
ANT MED 1			CETRD AM	CETRD AM
ANT MED 2				
OTH MED 1				DEXAMETH
HCG T MED 1			NVRL 1000	
HCG T MED 2			LUPR 4MG	
HCG T MED 3			LUPR 4MG	
LUTEAL MED1				
LUTEAL MED2				
Retrieval Date				
ESTRADIOL (pg/mL)		2239	2592	1783
PROGESTERONE (ng/mL)		6.8	1.16	0.97
LH (milliintl units/mL)		7.1	1.3	1.6
HCG SERUM (milliintl units/mL)		496.0		
US IMPRESS			P 11	
US LTOV FO1 (mm)			20	17
US LTOV FO2 (mm)			16	14
US LTOV FO3 (mm)			9	9
US LTOV FO4 (mm)			8	8
US RTOV FO1 (mm)			22.5	21
US RTOV FO2 (mm)			17.5	16.5
US RTOV FO3 (mm)			17	14
US RTOV FO4 (mm)			17	13
US RTOV FO5 (mm)			16.5	13
US RTOV FO6 (mm)			16	12
US RTOV FO7 (mm)			15	11
US RTOV FO8 (mm)			12.5	10.5

US RTOV FOT			7	5
US RT OV COM				plus 4-5
US EMC			10 mm	10 mm
US PATTERN			Triple	Triple

Turner syndrome and fertility preservation

Oocyte Cryopreservation for Fertility Preservation in Postpubertal Female Children at Risk for Premature Ovarian Failure Due to Accelerated Follicle Loss in Turner Syndrome or Cancer Treatments

K. Oktay MD ^{1,2,*}, G. Bedoschi MD ^{1,2}

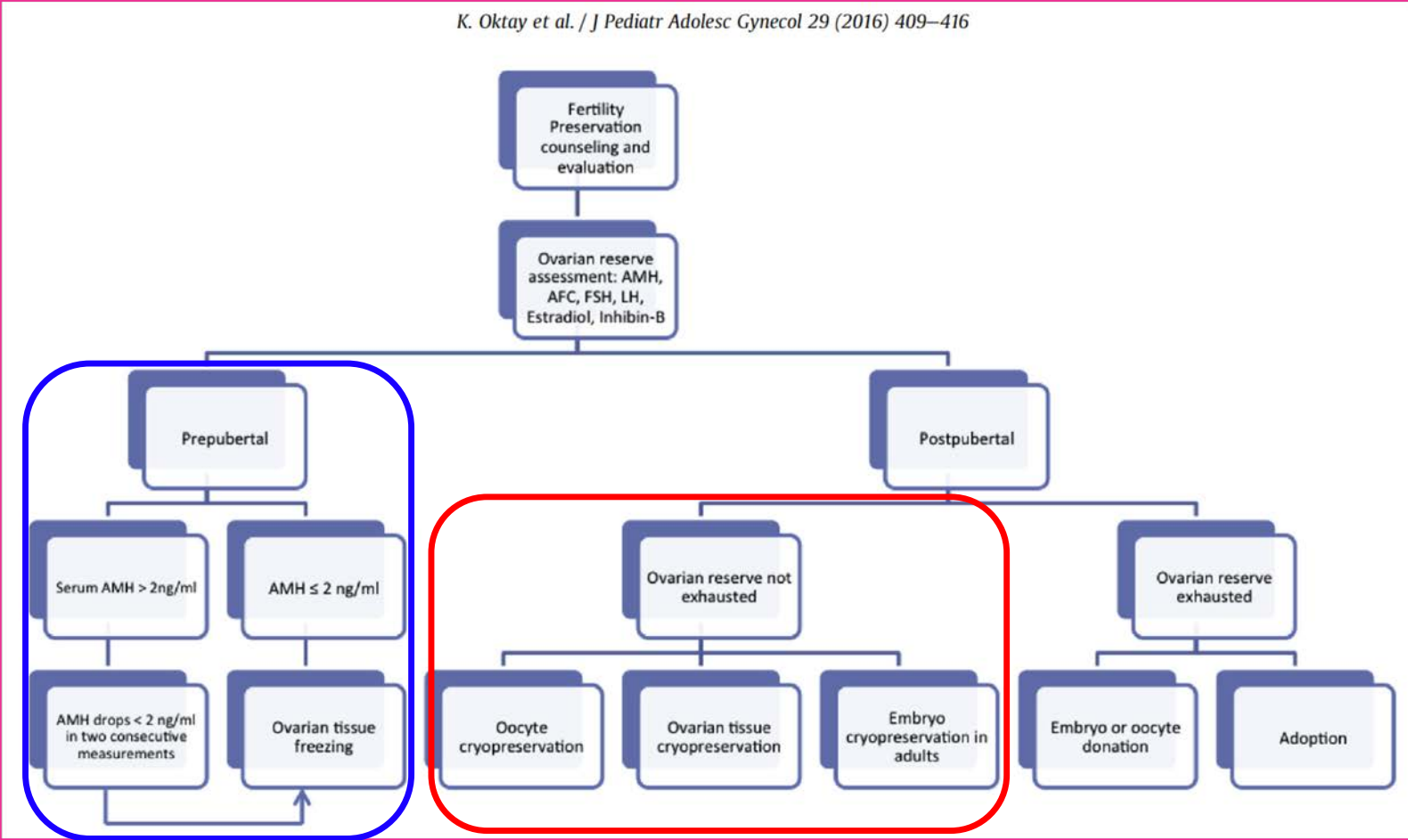
Table 1
Indications for Oocyte Cryopreservation and Ovarian Reserve Assessment

Characteristics	Case 1	Case 2	Case 3	Case 4	Case 5
Age (y)	13	14	13	15	14
Clinical diagnosis	Turner syndrome	Turner syndrome	Turner syndrome	Germ cell tumor	Acute lymphoblastic leukemia
Serum FSH (mIU/ml)	5.7	5.3	5.6	5.6	7.8
Serum LH (mIU/ml)	3.9	9.5	5.3	9.2	8.1
Serum estradiol (ng/ml)	15.1	65.2	33.5	66	28.15
Serum AMH (ng/ml)	1.59	0.9/1.7*	0.76	1.6	0.8/1.3 [†]
Serum Inhibin B (pg/ml)	54.8	<30.0	47.2	-	-
Antral follicle count	6	12	6	11	5

Turner mosaic, 45XO, 46XX

Turner syndrome and fertility preservation

K. Oktay et al. / J Pediatr Adolesc Gynecol 29 (2016) 409–416



ASRM Practice Guidelines, 2012

Increased maternal cardiovascular mortality associated with pregnancy in women with Turner syndrome

Practice Committee of the American Society for Reproductive Medicine
American Society for Reproductive Medicine, Birmingham, Alabama

Perinatal complications:

- ❑ Pregnancy loss
- ❑ Aneuploidy
- ❑ IUGR
- ❑ LBW
- ❑ Prematurity
- ❑ PIH

- ❖ Relative contraindication to pregnancy
 - ❖ *Use of surrogacy and adoption should be encouraged*
 - ❖ 2% mortality risk (1:100,000 in general ob population)
 - ❖ Careful prenatal evaluation (cardiology, MFM)
 - ❖ Abnormal cardiac MRI → absolute contraindication

Fertility in Turner syndrome: patient resources

TURNER SYNDROME FOUNDATION

Search Here Go

DONATE RESEARCH PROFESSIONAL PATIENT HEALTH RESOURCES TAKE ACTION TEAM TSF JOIN

Reproductive Health

the Oncofertility Consortium AT NORTHWESTERN UNIVERSITY

Turner Syndrome

Online Resources for More Information on Fertility Preservation Options

Can women with Turner syndrome get pregnant naturally?
Yes. Approximately 1-2% of women with Turner syndrome get pregnant naturally.

Is pregnancy dangerous in some women with Turner syndrome?

Turner Syndrome Society of the United States

Empowering. Educating. Supporting Since 1987

Account Log-in
Create an Account

DONATE

Home About Turner Syndrome Living with Turner Syndrome Events Get Involved Donate About TSSUS

Education and **Learning**

The majority of girls and women with Turner syndrome

Patient EB: initial presentation

- ❖ 17yo Go female-to-male transgender
- ❖ Desired sex reassignment surgery, s/p breast reduction
- ❖ Presented prior to initiation of androgen therapy
 - ❖ Mother conducted extensive research prior to consult
- ❖ Discussion regarding need for frequent monitoring
 - ❖ Blood sampling
 - ❖ Transvaginal ultrasound

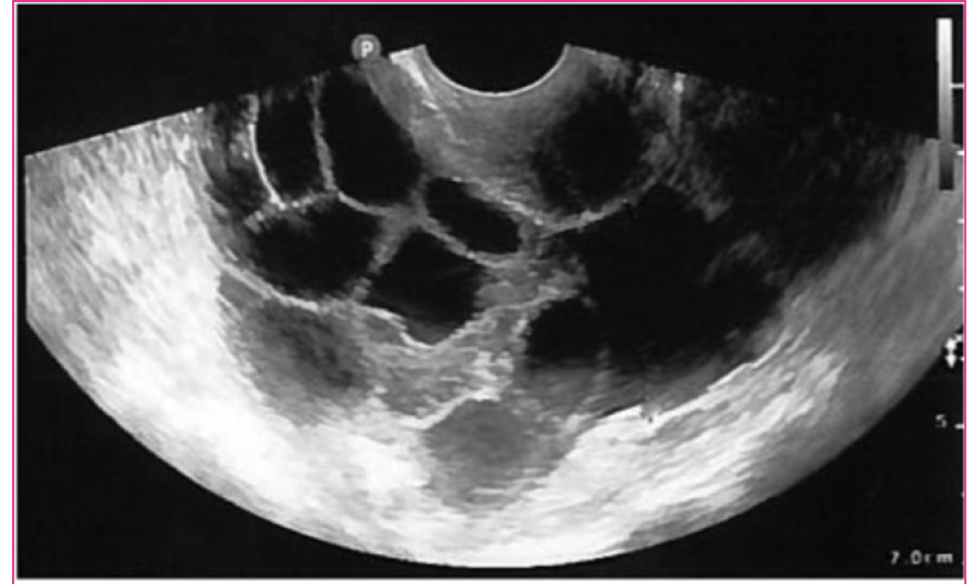Patient EB: ovarian reserve and prescreening

- ❑ Ovarian reserve markers:
 - ❑ FSH 5.7 mIU/mL
 - ❑ E2 60 pg/mL
 - ❑ AMH 3.5 ng/mL
 - ❑ AFC 40

- ❑ Comprehensive team
 - ❑ Oncofertility specialist
 - ❑ Patient navigator
 - ❑ Clinical psychologist
 - ❑ Individually
 - ❑ Family
 - ❑ Embryologist
- ❑ Staff education
- ❑ Single provider

Patient EB: ovarian stimulation and outcome

- ❖ BCP antagonist protocol
 - ❖ 10 days of stimulation
 - ❖ Max E2 = 2811 pg/ml
 - ❖ GnRHa trigger
- ❖ Cycle outcome:
 - ❖ 39 oocytes retrieved
 - ❖ *35 mature oocytes vitrified*
- ❖ Initiated androgen therapy with next menses



Fertility preservation for transgender patients

GYNECOLOGICAL
ENDOCRINOLOGY

ISSN: 0951-3590 (print), 1473-0766 (electronic)

Gynecol Endocrinol, Early Online: 1-4
© 2014 Informa UK Ltd. DOI: 10.3109/09513590.2014.920005

CASE REPORT

Fertility preservation in the transgender patient: expanding oncofertility care beyond cancer

Sumer Allensworth Wallace¹, Kiara L. Blough¹, and Laxmi A. Kondapalli^{1,2}

Access to fertility services by transgender persons: an Ethics Committee opinion

Ethics Committee of the American Society for Reproductive Medicine
American Society for Reproductive Medicine, Birmingham, Alabama

Adolescent health brief

Fertility Preservation for Transgender Adolescents

Diane Chen, Ph.D. ^{a,b,c,d,*}, Lisa Simons, M.D. ^{a,d}, Emilie K. Johnson, M.D., M.P.H. ^{e,f},
Barbara A. Lockart, D.N.P., A.P.N./C.N.P.-A.C. & P.C., C.P.O.N. ^{g,h}, and Courtney Finlayson, M.D. ^{d,i}

FP in transgender: patient resources



UCSF University of California, San Francisco | About UCSF | Search UCSF | UCSF Medical Center

Increasing access to comprehensive, healthcare services for trans communit

center of excellence FOR TRANSGENDER health

- About Us: Meet Center leadership and staff
- Programs & Services: Learn how we work to improve trans health
- Learning Center: Access current guidelines, articles, and online learning
- Connect: Find partners and leaders

Table of Contents: **Fertility options for transgender persons**

Introduction Primary author: Paula Amato, MD



致我们的中国患者 English

CCRM

- LOCATIONS
- CAUSES OF INFERTILITY
- TREATMENT & CARE

FERTILITY TREATMENT FOR TRANSGENDER COUPLES



Human Fertilisation & Embryology Authority

Home | Contact us

I am... | Treatments | Donation | Choose a clinic

Information for trans and non-binary people seeking fertility treatment



GAY PARENTS to be our BLOG About

for GAY MEN for LESBIANS for TRANS SUCCESS RATES FINANCIAL

FOR TRANS

Getting Started: Family Building For Transgender Patients



HEALTH 10/31/2018 11:03 am ET | Updated Nov 01, 2018

Transgender People Often Have To Choose Between Their Fertility And Their Transition

Experts recommend that trans people preserve their fertility first if they know they want to be parents. But there are serious barriers in the way.

By Anna Almendrala



COURTESY OF THE DANIELS FAMILY
Cass and Cammie Daniels with their newborn daughter, Reece.



Clinical Cases in Oncofertility

Laxmi A Kondapalli, MD MSCE
Colorado Center for Reproductive Medicine

Oncofertility Consortium Annual Meeting
November 15, 2018 ♦ Chicago, IL






Case Studies

Kristin N Smith

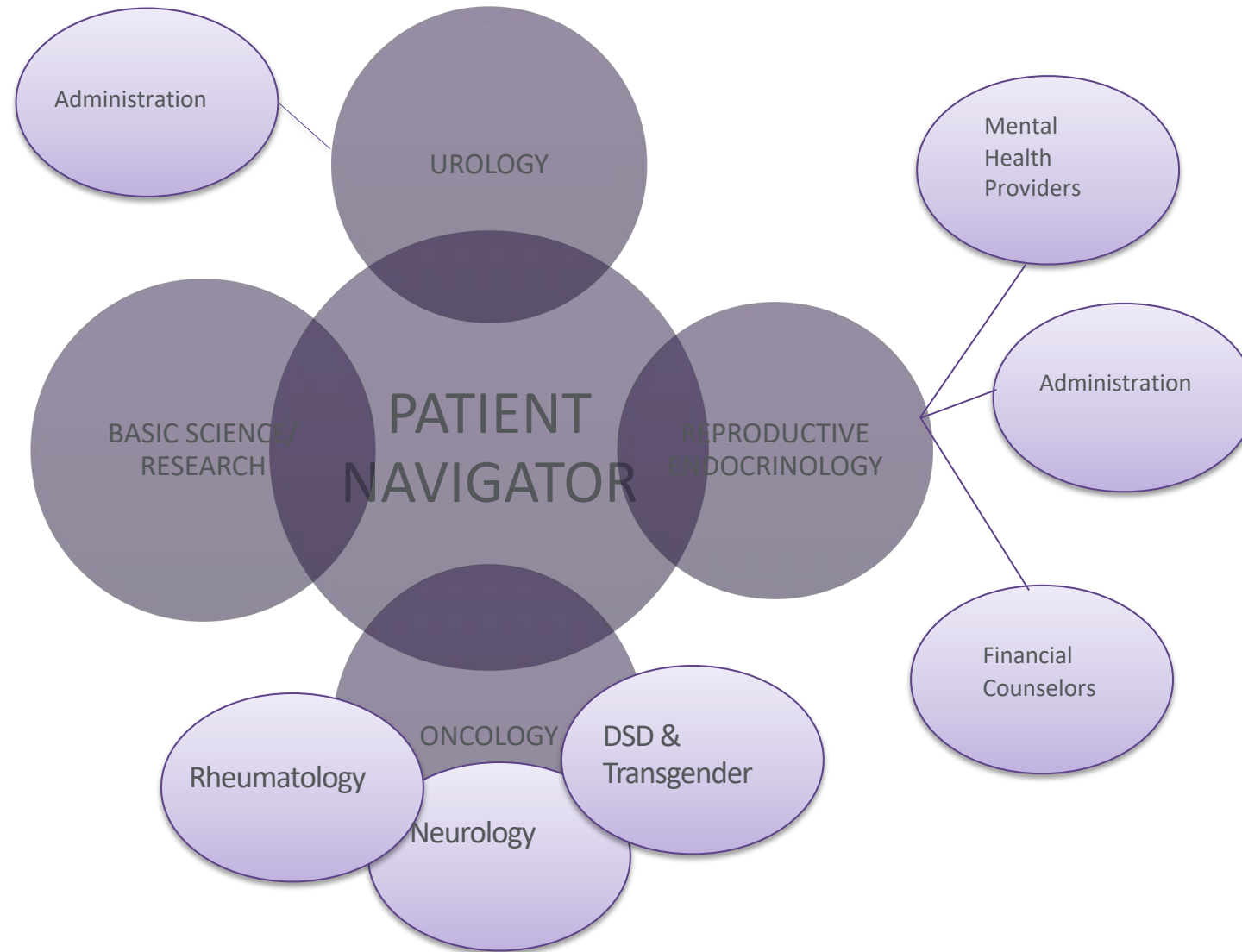
Program Manager for Fertility Preservation

Patient Navigation

- Process by which an individual – a Patient Navigator – guides patients through and around barriers in a complex healthcare environment to help ensure diagnosis and treatment.*

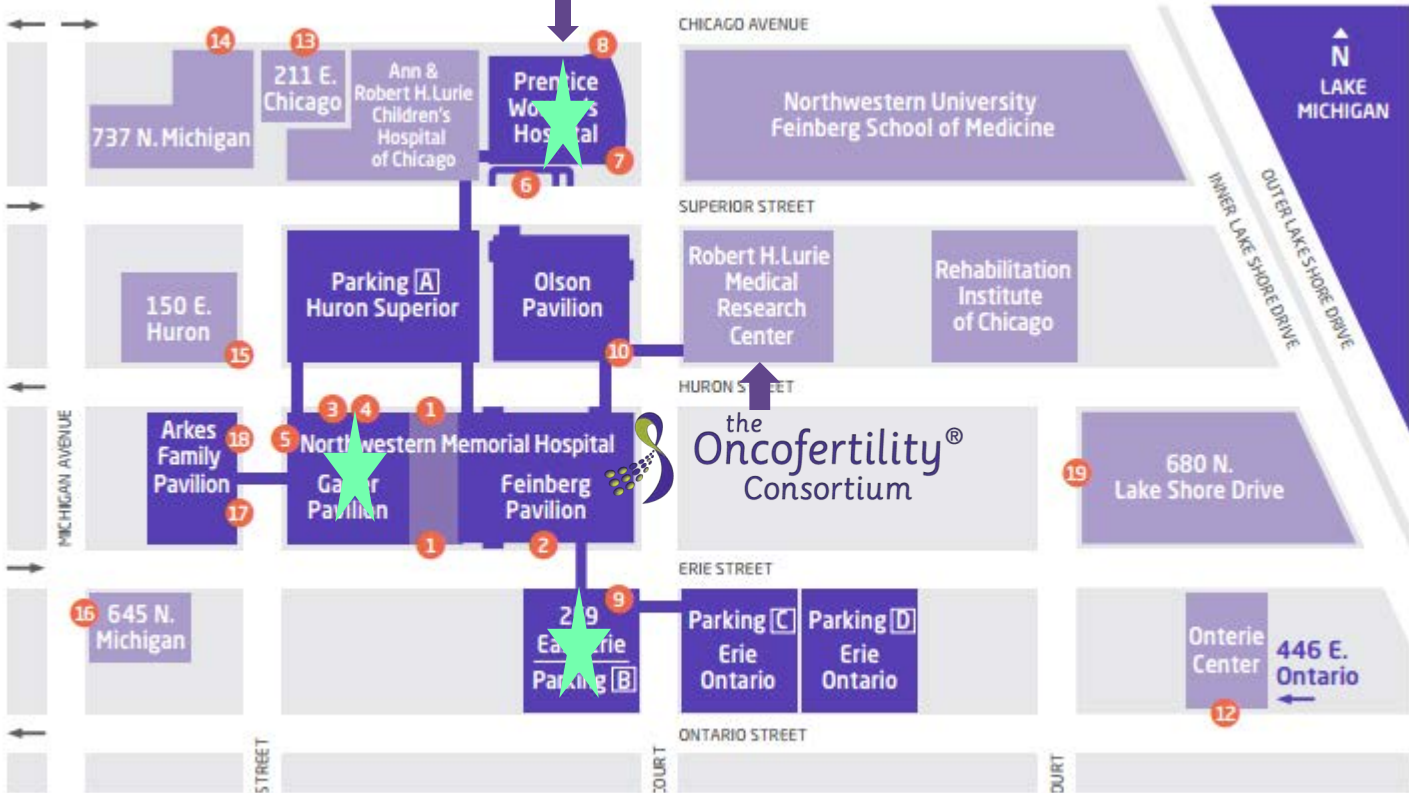


The Team at Northwestern



Northwestern Facilities

Guide to the Downtown Medical Campus



Intake Forms

- Patient Demographic
 - Name, DOB, address, preferred phone, email
- Disease
 - Stage, location, treatment plan, treating physician
- Menstrual history
 - LMP, onset of menses, cycle length, OCP use
- General Health History
 - Surgical hx, medical hx, alcohol & tobacco use, exercise, dietary restrictions, allergies
- Fertility Preservation Options
- Additional office visit
 - REI/Urology visits scheduled
- Financial Assistance/Insurance

Case #1

JT – 26 y/o male

- Presented in July 2017 to ED w/ persistent abdominal pain and 30 lb weight loss.
- CT showed multiple liver lesions w/ largest measuring up to 15 cm
- Biopsy consistent with hepatocellular carcinoma
- Transferred back to Chicago (was in school OOS)
- Social History: Engaged
-
- Underwent Y-90 / discussion of immunotherapy vs chemotherapy
- Patient chose FOLFOX
 - Declined sperm banking
- 12/17 – progression of disease in his lungs
- Offered clinical trial / Sorafenib

Case #1

JT – 26 y/o male

- Showed back up in May 2018
 - Agreed to start Sorafenib
- Appt in June 2018
 - Discussion around terminal nature of his disease
 - Family continued to want aggressive treatment
- 3 days later, patient was admitted to hospital following one day of confusion/agitation and vomiting
 - Hepatic encephalopathy
 - Intubated for airway protection
 - Mom, Dad and fiancé are his team
- Enter Fertility Preservation

Case #2

ILD – 31 y/o female

- Presented in April 2018 w/ lymphadenopathy of neck and groin for 2 weeks, progressive fatigue night sweats
 - Initially attributed to a cold
 - Seen in urgent care - sent to ED (WBC 24.9)
 - Admitted to Oncology service for further work up
 - Started on E1910 Induction Therapy (2 cycles)

Fertility Preservation

- Lupron 3.75 mg depot injection (2 months)

Case #2

ILD – 31 y/o female

- Patient underwent stimulation cycle

	Baseline	7	9	11	13	14	15
Estradiol		53	127	294	451	636	744
Right	AFC 7	AFC 2	AFC 2	13 X 2	16,14	20,15	19X2
Left	AFC 3	AFC 2	AFC 3	11,10,4	18,13	19, 14	22, 15
Endometrial Stripe		5.09	5.28	9.33	10.27	12.29	13.59

2 eggs retrieved, fertilized and frozen

Case #2

ILD – 31 y/p

- 3 months later, came back from cycle #2

	Baseline	4	6	8	10	11	12
Estradiol	<20	<20	70	199	361	377	683
Right	29 cyst	27 cyst	19 cyst	18 cyst		24	24
Left	AFC 1	AFC 1	10 15, 12	16, 14	19, 15, 10	22, 16, 10	
Endometrial Stripe		7.25	4.28	5.93	7.49	11.59	11.59

3 eggs retrieved, 1 mature (2 atretic), 1 fertilized

Thank You

ksmith@nm.org

(312) 503-3378

www.fertilitypreservation.northwestern.edu

www.oncofertility.northwestern.edu

www.savemyfertility.org

CASE PRESENTATION

Hodgkin Lymphoma in a Young Adult Female

Case 1

- 20 yo G0 with stage IIA nodular sclerosing Hodgkin's Lymphoma (HL).
- Swollen right neck with two year history of cough when supine.
- CT confirmed cervical and mediastinal lymphadenopathy.
- Biopsy c/w HL treated with ABV therapy w/o dacarbazine.
- Disease progression noted at four week end of therapy PET.
- Plan for chemotherapy with rituximab, ifosfamide, carboplatin and etoposide (R-ICE) followed by autologous stem cell transplant (ASCT).

Case 1 (continued)

- Counseled regarding risk of oocyte freezing with proximity to chemotherapy.
- Ovarian reserve: AMH 3.08 ng/dl, FSH 4.9 mIU/ml, E2 99 pg/ml.
- Decision to proceed with ovarian tissue cryopreservation (OTC).
- Stand alone uncomplicated laparoscopic removal of right ovary.
- Ovary sent for processing at external REI lab.
- Nexplanon placed for contraception and GnRHa therapy started.
- Proceeded with ASCT with BEAM.

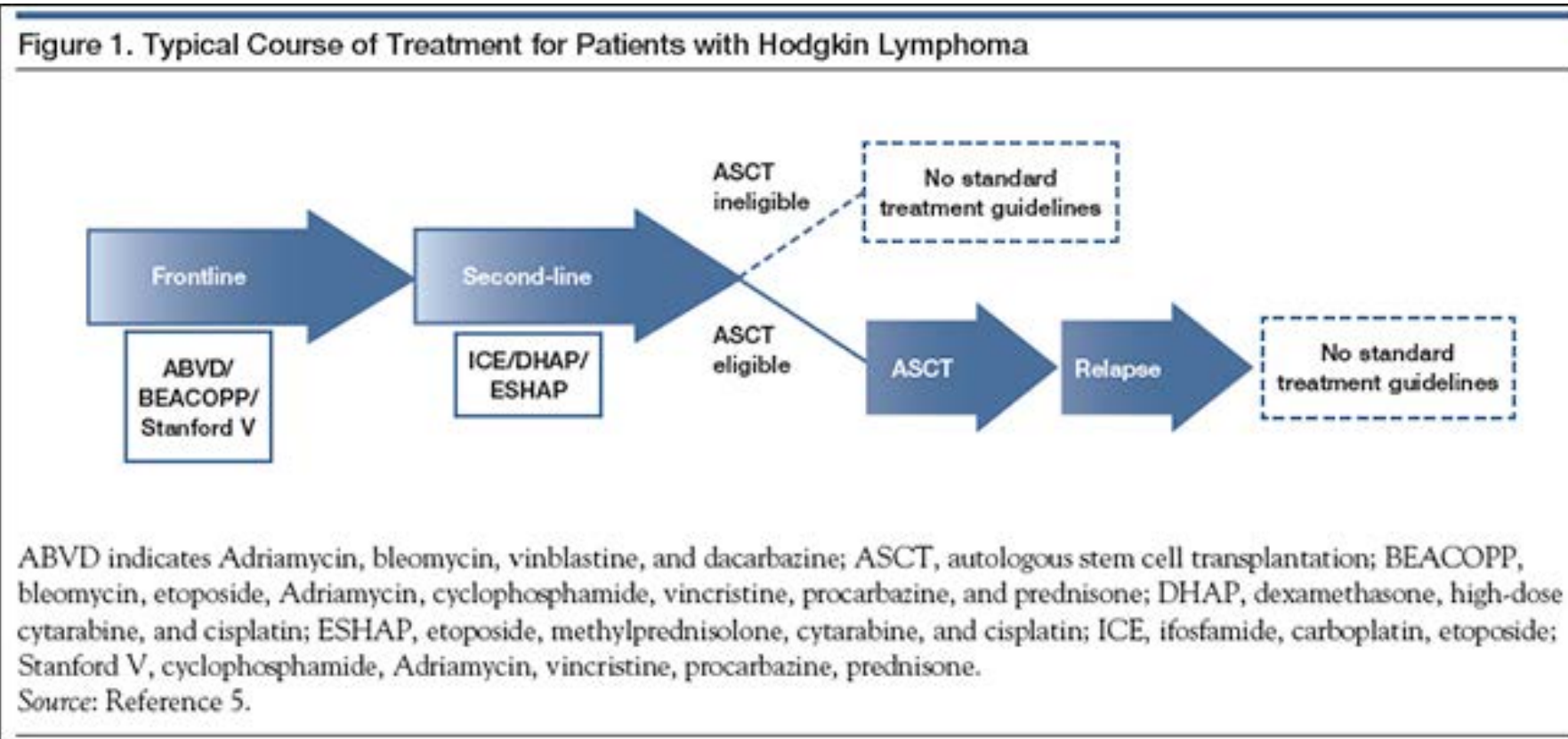
Case 2

- 20 yo G2P2 with stage IIB classical nodular sclerosing HL.
- Stiff neck, palpable nodules and associated night sweats.
- Positive pregnancy test at time of planned CT scan.
- ABVD at 22 weeks modified to AVD due to bleomycin toxicity.
- Delivered vaginally at 33 weeks due to severe preeclampsia.
- Completed chemotherapy with disease progression at four week end of therapy PET.
- Plan for salvage chemotherapy and ASCT.

Case 2 (continued)

- Counseled regarding risk of oocyte freezing with proximity to chemotherapy.
- Ovarian reserve: AMH 0.93 ng/dl, FSH 1.7 mIU/ml, E2 184 pg/ml.
- Decision to proceed with ovarian tissue cryopreservation (OTC).
- Stand alone uncomplicated laparoscopic removal of left ovary.
- Ovary sent for processing at external REI lab.
- Nexplanon placed for contraception and GnRHa therapy started.
- Proceeded with ASCT 2 months later as scheduled.

Hodgkin Lymphoma Treatment



Risk factors for impaired gonadal function in female Hodgkin lymphoma survivors: final analysis of a retrospective multicenter joint study from Italian and Brazilian Institutions

Table 3. Univariate and multivariate analysis of factors associated with impaired gonadal function

	Univariate regression analysis			Multivariate regression analysis		
	OR	CI 95%	p-value	OR	CI 95%	p-value
Age (years)						
≤30	1			1		
>30	2.4	1.3–4.6	0.005	2.99	1.39–6.41	0.005
Stage						
I–IIA	1					
IIB–IV	2.28	1.2–4.3	0.011			
Front-line therapy						
ABVD and VBM	1			1		
COPPEBVCAD/st BEACOPP	2	1.02–4	0.015	2.44	1.06–5.66	0.03
Escalated BEACOPP	2.87	0.94–8.8	0.06	4.24	1.12–16	0.03

- Endpoints: irreversible amenorrhea and infertility
- ABVD therapy had a better gonadal prognosis than treatment with alkylators
- **However, 20% of patients > age 30 with ABVD had gonadal compromise – attributed to salvage therapy**

Determinants of ovarian function after response-adapted therapy in patients with advanced Hodgkin's lymphoma (RATHL): a secondary analysis of a randomised phase 3 trial

Richard A Anderson, Rachel Remedios, Amy A Kirkwood, Pip Patrick, Linsey Stevens, Laura Clifton-Hadley, Tom Roberts, Chris Hatton, Nagesh Kalakonda, Don W Milligan, Pam McKay, Clare Rowntree, Fiona M Scott, Peter W M Johnson (2018)

- Prospective cohort study with stage IIB-IV or IIA HL
- 3 year fixed annual follow-up of ovarian function with AMH and FSH.
- 57 participants received ABVD or AVD (ABVD-AVD group).
- Ten received BEACOPP-14 or escalated BEACOPP (BEACOPP group).
- At 1 year after chemotherapy
 - AMH concentrations recovered to a median of 10.5 pmol/L (**0.8 ng/dl**) in the ABVD-AVD group.
 - Little recovery after BEACOPP (median 0.11 pmol/L (**0.009 ng/dl**)).

Determinants of ovarian function after response-adapted therapy in patients with advanced Hodgkin's lymphoma (RATHL): a secondary analysis of a randomised phase 3 trial

Richard A Anderson, Rachel Remedios, Amy A Kirkwood, Pip Patrick, Linsey Stevens, Laura Clifton-Hadley, Tom Roberts, Chris Hatton, Nagesh Kalakonda, Don W Milligan, Pam McKay, Clare Rowntree, Fiona M Scott, Peter W M Johnson

- Participants ages 35 years or older in the ABVD-AVD group:
 - AMH 37% (SD 10) of before treatment concentrations
- Participants younger than 35 years:
 - Full AMH recovery to 127% (SD 12) ($p < 0.0001$).
- FSH < 25 IU/L for 95% of women < 35 years in ABVD-AVD group by 2 years; dependent on age ($HR 0.49$, 95% CI 0.37–0.65; $p < 0.0001$).
- Age-specific considerations of fertility preservation procedures should be considered before treatment in HL.

Subfertility/Infertility Risk

Low Risk < 20%	Medium Risk >30 and <70%	High risk > 80%
ALL	AML	BMT Conditioning
Wilms' tumor	Hepatoblastoma	Whole body irradiation
Soft-tissue sarcoma: stage I	Osteosarcoma	Pelvic/testicular irradiation
Retinoblastoma	Ewing's sarcoma: non-metastatic	
Germ-cell tumors (fertility sparing)	Soft-tissue sarcoma: stage II/III	Hodgkin: alkylator
Hodgkin: Non-alkylating	Neuroblastoma	Soft-tissue sarcoma: stage IV
	Hodgkin: alternating alkylator tx	Metastatic Ewing's sarcoma
CNS: surgery and irradiation < 24 Gy	CNS irradiation >24 Gy and <30 Gy	

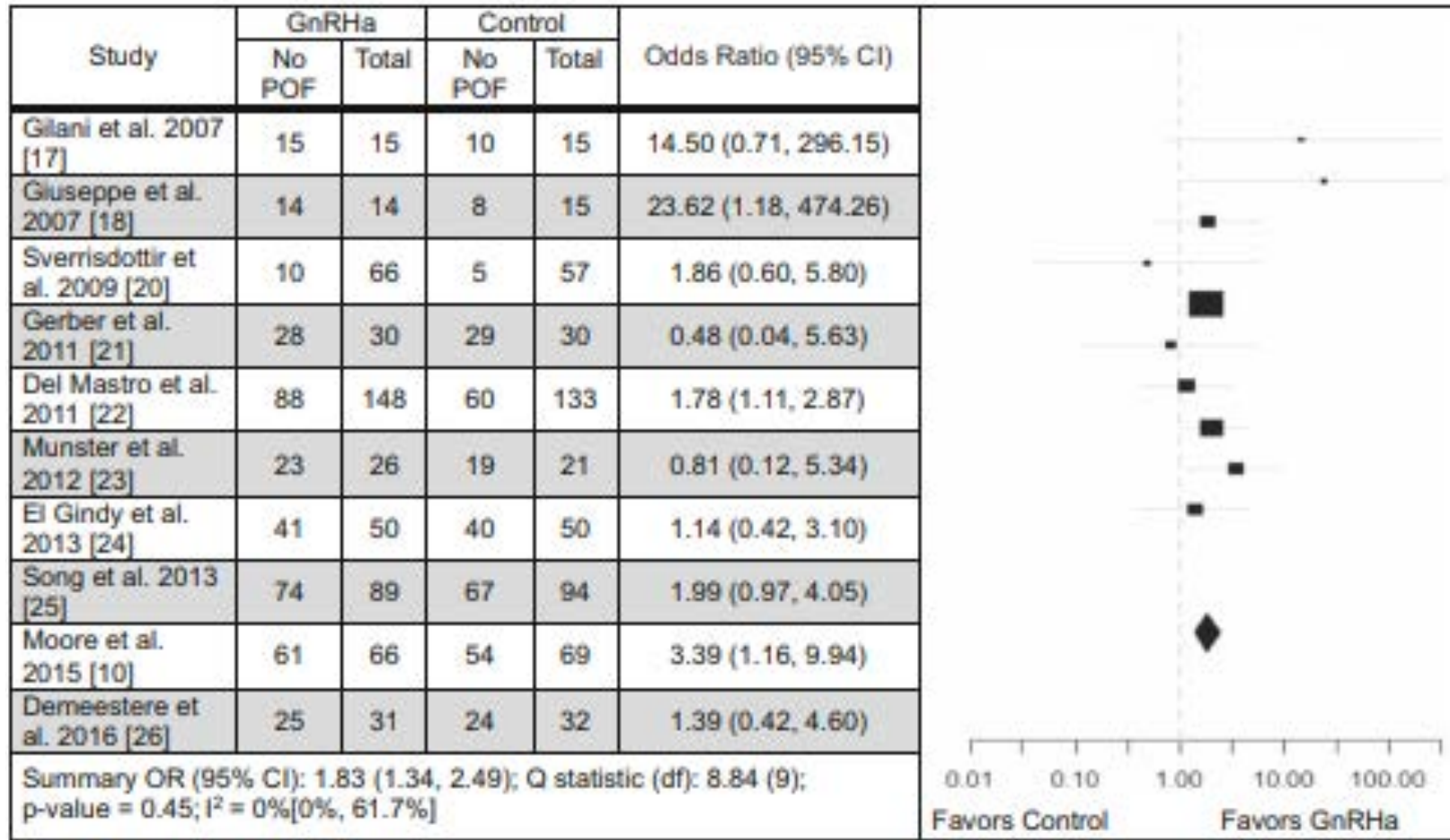
Gonadotoxicity of “Newer” Agents

- Paclitaxel, docetaxel (taxanes used in AC protocols)
- Oxaliplatin
- Irinotecan
- Brentuximab/Rituximab ***
- Bevacizumab
- Cetuximab
- Trastuzumab
- Erlotinib
- Imatinib
- Immune-modulators

Fertility Preservation Methods

Standard Methods	Investigational Methods
Mature oocyte cryopreservation (35 - 50% success rate)	In vitro maturation (IVM) for oocyte cryopreservation
Embryo cryopreservation (40% success rate)	Ovarian tissue freezing
Ovarian transposition (88-90% success rate)	GnRHa ovarian suppression
Ovarian shielding (75-80% success rate)	

GnRHa and Ovarian Protection



Ovarian Protection During Chemotherapy for Hodgkin Lymphoma

Study	n	Population	Conclusion	GnRHa	Endpoints
Prospective non-randomized Blumenfeld 2008	65	Hodgkin Lymphoma	No Benefit	Goserelin q4wks	POI Pregnancy
Prospective randomized Giuseppe 2017	29	Hodgkin Lymphoma	No Benefit	Triptorelin q4wks Triptorelin q12wks	POI AMH AFC
Retrospective Behringer 2012	18	Hodgkin Lymphoma	Benefit	Various GnRHa	POI Pregnancy
*Prospective randomized Behringer 2010	23	Advanced Hodgkin Lymphoma	No Benefit (BEACOPP)	Goserelin q4wks	POI

- GnRHa therapy cannot be recommend for fertility preservation in HL

Menstrual suppression

- Leuprolide acetate 11.25 mg IM or 22.5 mg SC every 12 weeks during chemotherapy for menstrual suppression for patients are risk of profound anemia ^{Bates et al 2011.}
 - administered prior to chemotherapy
 - final dose to be administered at final chemotherapy infusion.
- ASCO: when proven fertility preservation methods...are not feasible...GnRHa may be offered to individuals in the hope of reducing the likelihood of chemotherapy-induced ovarian insufficiency ^{Oktay 2018.}
- Norethindrone acetate add-back to minimize hot flashes and protect bone ^{DiVasta 2013.}
 - start with or before leuprolide and discontinue 12 weeks after final dose

Bates et al. *Pharmacotherapy* 2011;31(11):1092–1110.

DiVasta et al. *Curr Opin Obstet Gynecol* 2013, 25:287–292

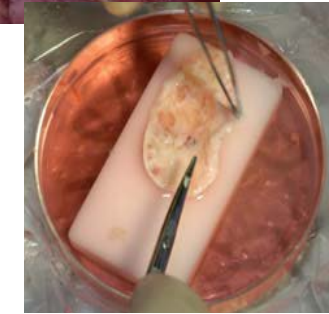
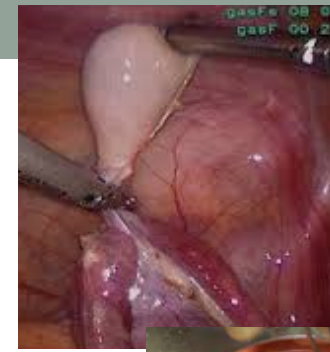Oktay, K., et al., *J Clin Oncol*, 2018. 36(19): p. 1994-2001.

REVIEW ARTICLE

Edward W. Campion, M.D., *Editor*

Fertility Preservation in Women

Jacques Donnez, M.D., Ph.D., and Marie-Madeleine Dolmans, M.D., Ph.D.



- 130 children born worldwide.
- Age range from adolescence to mid 30's.
- Mean gestational age 39 for 40 of the patients with follow-up.
- Half of singletons conceived naturally; twins by IVF.
- Suggest that OTC is becoming an established fertility preservation method and should no longer be considered experimental.

Donnez et al. NEJM; 2017;377(17):1657-1665

Jensen et al. J Assist Reprod Genet (2017) 34: 325

Pacheco et al. Reprod Sci 2017

Can we assess the reproductive window?

AMH: Clinical Use and Limitations

¹ AMH ng/ml	Implication
Low (0.5)	Impending onset of premature menopause
Low (< 1.0)	Limited egg supply
Midrange (1-3.5)	Normal testing
Elevated (>3.5)	PCO or PCO-like ovaries Risk of OHSS

Limitations²:

Specimen handling and processing affects results.

Intra-subject variability.

Does not reliably predict pregnancy rates.

Not standard of care -
reasonable in survivors ≥ 25 .

¹Modified, Toner. Fertil Steril 2013

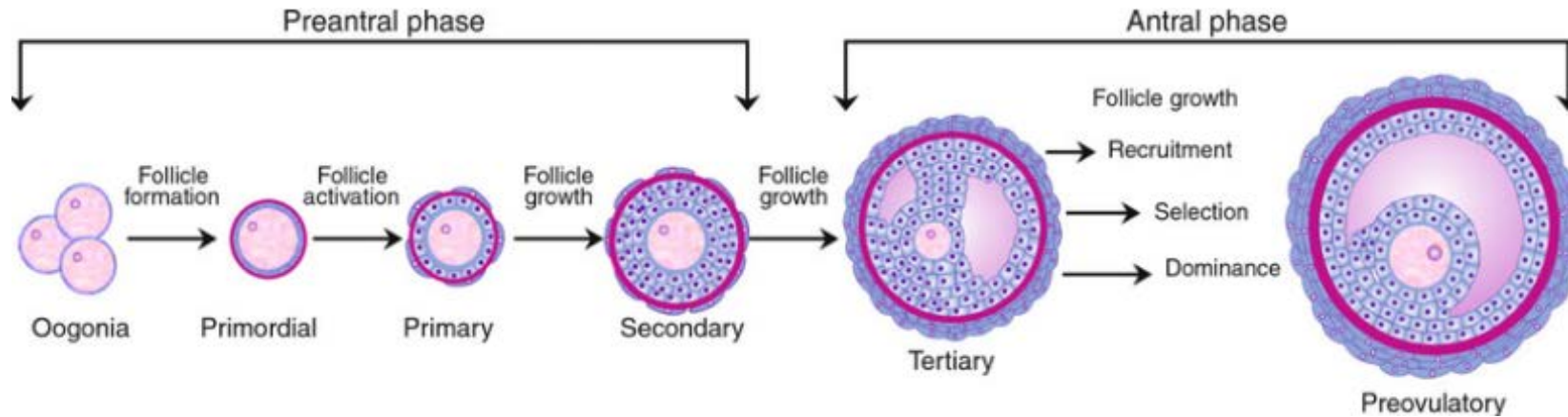
²Broer. Hum Reprod Update. 2013;19(1):26-36

COG LTFU 2013

Van Dorp et al., 2016

Regulation of ovarian follicular development in primates: facts and hypotheses.

Gougeon A¹.



- Growth span from primordial to pre-ovulatory follicle: 6 months.
- Risk of mutagenesis maximal during this maturation phase.
- Recommendation: delay conception for 6 months after completion of treatment.

Gougeon et al., Endocr Rev. 1996 Apr;17(2):121-55

Meirow et al., J Natl Cancer Inst Monogr. 2005;34:21-5

Chung et al., Fertil Steril 2013;99:1534-42

Mahajan. J Human Reprod Sci. 2015 Jan-Mar; 8(1): 3-13

Emergency IVF versus ovarian tissue cryopreservation: decision making in fertility preservation for female cancer patients

Karine Chung, M.D., M.S.C.E.,^a Jacques Donnez, M.D.,^b Elizabeth Ginsburg, M.D.,^c and Dror Meirou, M.D.^d

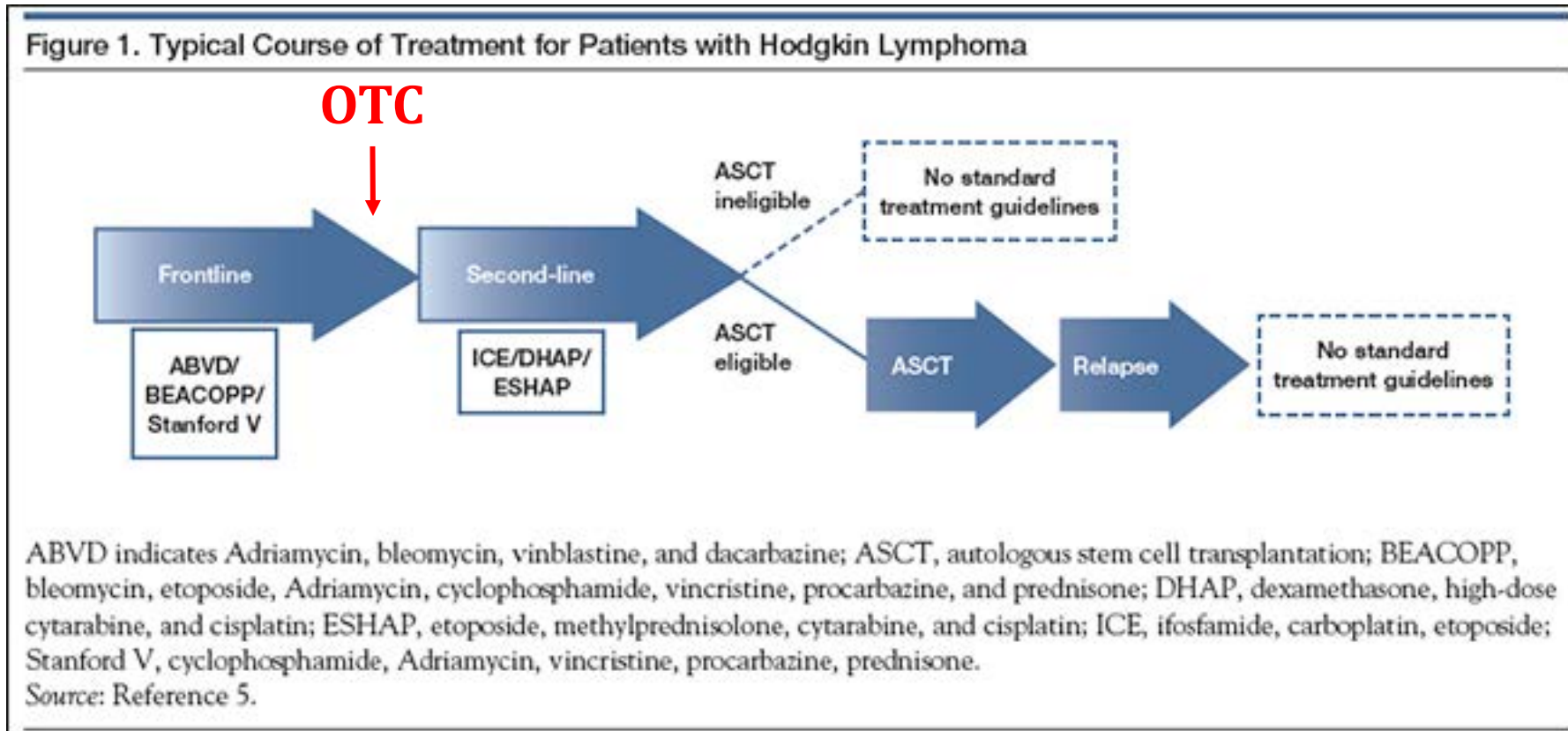
- Chemotherapy during follicle maturation shown to result in low stimulation rates and deleterious effects on reproductive outcome – high abortion and malformation rates as on animal studies^{Meirow}.
- Similar adverse effects are not observed in primordial follicles that survive long term after chemotherapy exposure.
- Cancer patients advised not to perform IVF cycles and to delay attempts to conceive until 6 months (time needed for human oocyte maturation) from completion of chemotherapy^{Kujjo}.

Chung et al, Fertil Steril 2013;99(6):1534-1542.

Kujjo LL et al. PLoS One 2011;6:e17877.

MeirowD, Schiff E. JNCI Monogr 2005;34:21–5.

Hodgkin Lymphoma Treatment and OTC



Assessing the Reproductive Window

A proposed use of ovarian reserve markers:

- Baseline AMH to assess ovarian reserve prior to cancer treatment.
- Serial AMH every 6-12 months to follow rate of decline.
- Serial FSH every 6-12 months to follow rate of rise.
- Refer to REI for fertility treatment when AMH levels fall below norms for age, FSH rises > 10 mIU/ml, or if patient desires preservation.

Take Home Points

- ASCT for HL is associated with a high risk of acute ovarian failure.
- Oocyte cryopreservation within 6 months of chemotherapy may be suboptimal and increase risk of adverse pregnancy outcomes.
- OTC may be utilized after non-sterilizing doses of chemotherapy and prior to ovarian ablative treatment.
- Consider baseline and yearly AMH and FSH post-treatment with referral to REI as parameters decline from age based norms.

Oncofertility options for a pregnant patient with acute leukemia (Case Study)

15 Nov 2018 - Chicago

Mahmoud Salama MD PhD

MBBCh, MSc, MD, PhD, EMD, MA
Adjunct Assistant Professor of Obstetrics & Gynecology
Department of Obstetrics and Gynecology
Feinberg School of Medicine
Northwestern University
Chicago, IL, USA.



UNIKLINIK
KÖLN




Northwestern
University



CASE REPORT



A successful multidisciplinary approach for treatment and for preserving the reproductive potential in a rare case of acute lymphocytic leukemia during pregnancy

Mahmoud Salama^{a,b} , Evgenia Isachenko^a, Sebastian Ludwig^a, Thomas Einzmann^a, Gohar Rahimi^a, Peter Mallmann^a and Vladimir Isachenko^a

^aDepartment of Obstetrics and Gynecology Medical Faculty, University of Cologne, Cologne, Germany; ^bOncofertility Consortium, Feinberg School of Medicine, Northwestern University, Chicago, IL, USA



UNIKLINIK
KÖLN

Salama et al (September 2018)
Gynecological Endocrinology Journal
The official journal of the International Society of Gynecological Endocrinology (ISGE).

Challenges

Acute leukemia during pregnancy raises several complex challenges including:

- 1) Being a rare condition** (prevalence 1 in 100,000 pregnancies), not enough data and evidence-based management strategies are available.
- 2) Being an acute hematological malignancy, it requires immediate initiation of anticancer therapy.**
In the first trimester: Administration of chemotherapy is considered teratogenic. In the second and third trimesters: Administration of chemotherapy may result in increased incidence of preterm labor, intrauterine growth restriction or fetal death although it does not increase the incidence of fetal anomalies or childhood malignancies.
- 3) In order to improve the maternal and fetal outcome,** proper management necessitates a high level of coordination and collaboration between oncologists, obstetricians, and neonatologists.
- 4) Survivorship, future fertility goals and fertility preservation options should be taken into account** especially in young patients who plan to have children in the future.

Patient

- **A 34-year-old female patient (Gravida 3, Para 0), severe obesity (Grade III, BMI > 40), recently diagnosed with B-Cell Acute Lymphocytic Leukemia (B-Cell ALL) during her 17th week of pregnancy.**
- **The patient decided to continue her pregnancy and signed the informed consent for the treatment plan** after receiving detailed information from her hematological oncology team about the disease, its challenges, prognosis and possible management and complications during pregnancy.
- **According to the hematological oncologists' treatment plan, chemotherapy needs to start immediately as described by the German Multicenter Study Group for Adult Acute Lymphoblastic Leukemia (GMALL 07/03). (GMALL: Trial No. 7, started in 2003-Present)**
- **According to GMALL 07/03:** The patient will receive immediately the prephase, induction I & II protocols, and at the beginning of her third trimester, will receive the consolidation I protocol with high dose methotrexate.

Chemotherapy (GMALL 07/03)

GMALL 07/03 Protocol	Day	Administered Chemotherapy
Prephase	1-5	<ul style="list-style-type: none"> Day 2-5 Dexamethason 3,33mg/m² p.o. 1-1-1 Day 3-5 Cyclophosphamid 200mg/m² 250ml NaCl 0,9% i.v. over 1h
Induction I	6-20	<ul style="list-style-type: none"> Day 6 Rituximab 375mg/m² 500ml NaCl 0,9% over 2h Day 6, 7 + 13-16 Dexamethason 3,33mg/m² p.o. 1-1-1 Day 6, 13, 20 Vincristin 2mg abs. 50ml NaCl 0,9% i.v. over 10min. Day 6-7, 13-14 Daunorubicin 45mg/m² 250ml NaCl 0,9% i.v. over 15 min Day 20 PEG-Aspargase 2000U/m² (max. 1 Amp) 100ml NaCl 0,9% i.v. over 2h Remission Control on Day 22
Induction II	24-45	<ul style="list-style-type: none"> Day 23, 44 Rituximab 375mg/m² 500ml NaCl 0,9% over 2h from Day 24 G-CSF s.c. Day 24, 44 Mesna 800mg abs. bolus i.v. (before Cyclophosphamid), Cyclophosphamid 1000mg/m² 500ml NaCl 0,9% i.v. 1h Day 26-29, 33-36, 40-43 Cytarabin 75mg/m² 250ml NaCl 0,9% i.v. 1h Day 28, 32, 39 Methotrexat 15mg abs. intrathecal, NaCl 0,9% 18mg abs. intrathecal Day 31-44 Mercaptopurin 60mg/m² p.o. 1-0-0 Day 44 PEG-Asp. 2000U/m² (max. 1 Amp.) 100ml NaCl 0,9% over 2h Remission Control on Day 44
Consolidation I	61-72	<ul style="list-style-type: none"> Day 60 Rituximab 375mg/m² 500ml NaCl 0,9% i.v. over 2h Day 61-65 Dexamethason 3,33mg/m² p.o. 1-1-1 Day 61 Vindesin 3mg/m² 50ml NaCl 0,9% i.v. Day 61 Methotrexat 150mg/m² 250ml NaCl 0,9% i.v. over 0,5h, Methotrexat 1350mg/m² 1000ml NaCl 0,9% i.v. over 23,5h (start Leucovorin-Rescue 42h after infusion) Day 64, 65 Etoposid 250mg/m² 1000ml NaCl 0,9% i.v. over 1h Day 65 Cytarabin 2000mg/m² 500ml NaCl 0,9% i.v. over 3h 2x daily with 12h in between. Cesarean section on Day 68

**Alkylating Agent
Cyclophosphamide**

Overall 5-year survival rate of ALL in Germany is 43.4% (vs 35.5% in USA). Pulte et al 2014 – PLOS One.

Fertility Preservation Decision-Making

- **Referral:** Due to the ongoing pregnancy and potential risks of chemotherapy-induced gonadotoxicity, and subsequent iatrogenic premature ovarian failure (POF) and fertility loss, the patient was referred to our Reproductive Medicine Department for fertility preservation counseling and further management before initiation of chemotherapy.
- **To overcome the aforementioned challenges, we considered ovarian tissue extraction and cryopreservation as the only feasible emergency fertility preservation option** in this case after counseling with the patient and obtaining the informed consent prior to the surgical procedure.
- **The right ovary was excised via laparoscopy one day before initiation of chemotherapy.**
- **Ovarian Tissue Cryopreservation (OTC) was performed according to our slow freezing protocol previously published by Isachenko et al 2016.**

Maternal & Fetal Outcome

- **The patient tolerated the surgery (laparoscopic unilateral oophorectomy) very well and on the next day chemotherapy was started and administered as planned.**
- The patient received the routine prenatal follow up, and **at the 30th week of gestation underwent a Cesarean section, as a result of fetal growth restriction** (fetal weight was below the 3rd percentile at the 29th week of gestation). Following Cesarean section, no maternal or major neonatal complications were recorded.
- **A morphologically normal baby boy weighing 980 g, 35 cm in length, was born with an Apgar score of 6, 8, 9 on the 1st, 5th and 10th minutes respectively.** The low-birth-weight baby was admitted at the neonatology unit for further routine observation and management.
- **The hospitalization course of the mother and the baby were uneventful.** After discharge from the hospital, the mother and the baby underwent routine follow up and no complications were recorded. Further chemotherapy for the mother is scheduled by hematological oncology team according to GMALL 07/03.

Fertility Preservation Outcome

- **A new assessment of endocrine and reproductive ovarian functions will be performed** after the patient completes the scheduled anticancer therapy and becomes fit and willing to have children again.
- **At that time, if the patient suffers from anticancer therapy induced POF, she may then use her cryopreserved ovarian tissue to restore her fertility.**
- **[To transplant or not to transplant - that is the question.](#)**
Silber SJ, Woodruff TK, Shea LD. Cancer Treat Res. 2010;156:41-54.
- **Autotransplantation of cryopreserved-thawed ovarian tissue should be absolutely contraindicated in leukemia patients** due to high risk of ovarian tissue contamination with hematological malignant cells or minimal residual disease (MRD).
- **The safest way to restore fertility in leukemia patients may be artificial ovary technology.**


Fertility Preservation Outcome

EXPERT REVIEW OF HEMATOLOGY, 2017
<https://doi.org/10.1080/17474086.2017.1371009>



Taylor & Francis
Taylor & Francis Group

SPECIAL REPORT



Advances in fertility preservation of female patients with hematological malignancies

Mahmoud Salama , Vladimir Isachenko, Evgenia Isachenko, Gohar Rahimi and Peter Mallmann

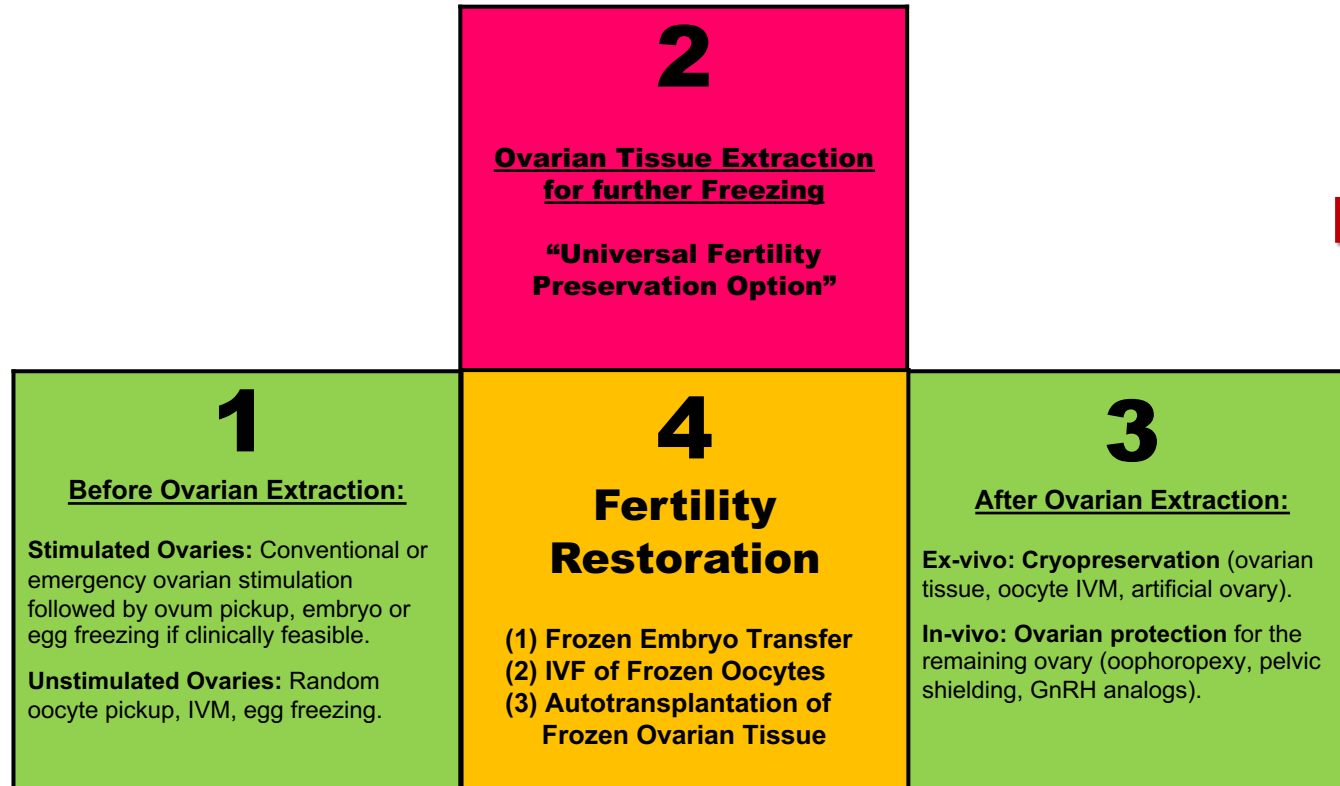
Department of Gynecology and Obstetrics, Medical Faculty, University of Cologne, Cologne, Germany



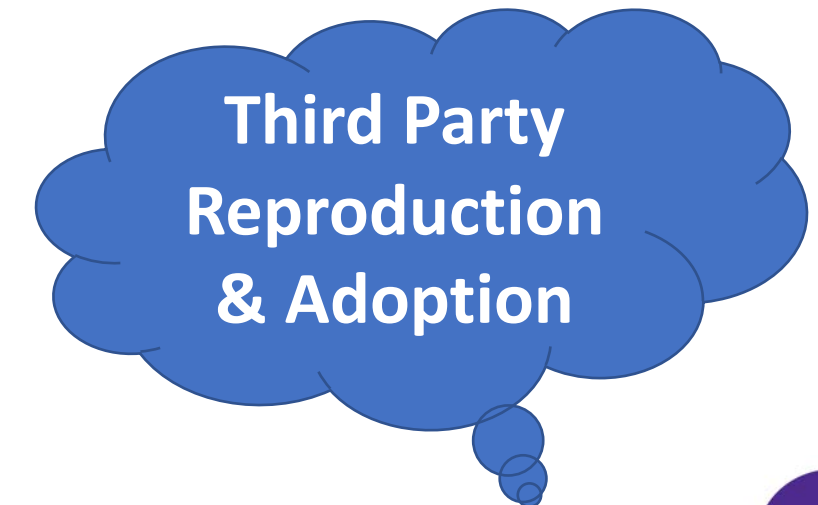UNIKLINIK
KÖLN

Salama et al (September 2017)
Expert Review of Hematology

Fertility Preservation Outcome



Ovarian Tissue Freezing is a
UNIVERSAL
Fertility Preservation Option



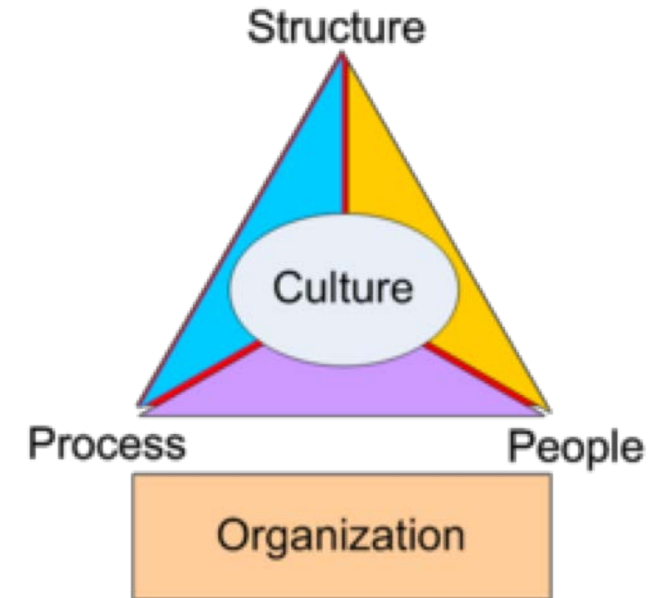Comprehensive Fertility Preservation & Restoration Strategy (Salama et al 2017)

Conclusion

- **A successful multidisciplinary management strategy** for treatment and for preserving the reproductive potential in a rare case of ALL during pregnancy has been achieved.
- **Several complex challenges require a highly skilled oncofertility team or at least a highly coordinated approach with oncologists, gynecologists, reproductive cryobiologists, obstetricians, and neonatologists.**
- **Pregnancy in the second trimester is neither a contraindication for ALL treatment nor for emergency fertility preservation via ovarian tissue extraction and further cryopreservation.** In the second trimester, ALL management strategies similar to those in non-pregnant patients can be successfully used.
- **Autotransplantation of cryopreserved-thawed ovarian tissue should be absolutely contraindicated in leukemia patients.**
- **The safest way to restore fertility in leukemia patients may be artificial ovary technology.**

What was not mentioned in this case study ?!!

Organizational Culture and Oncofertility

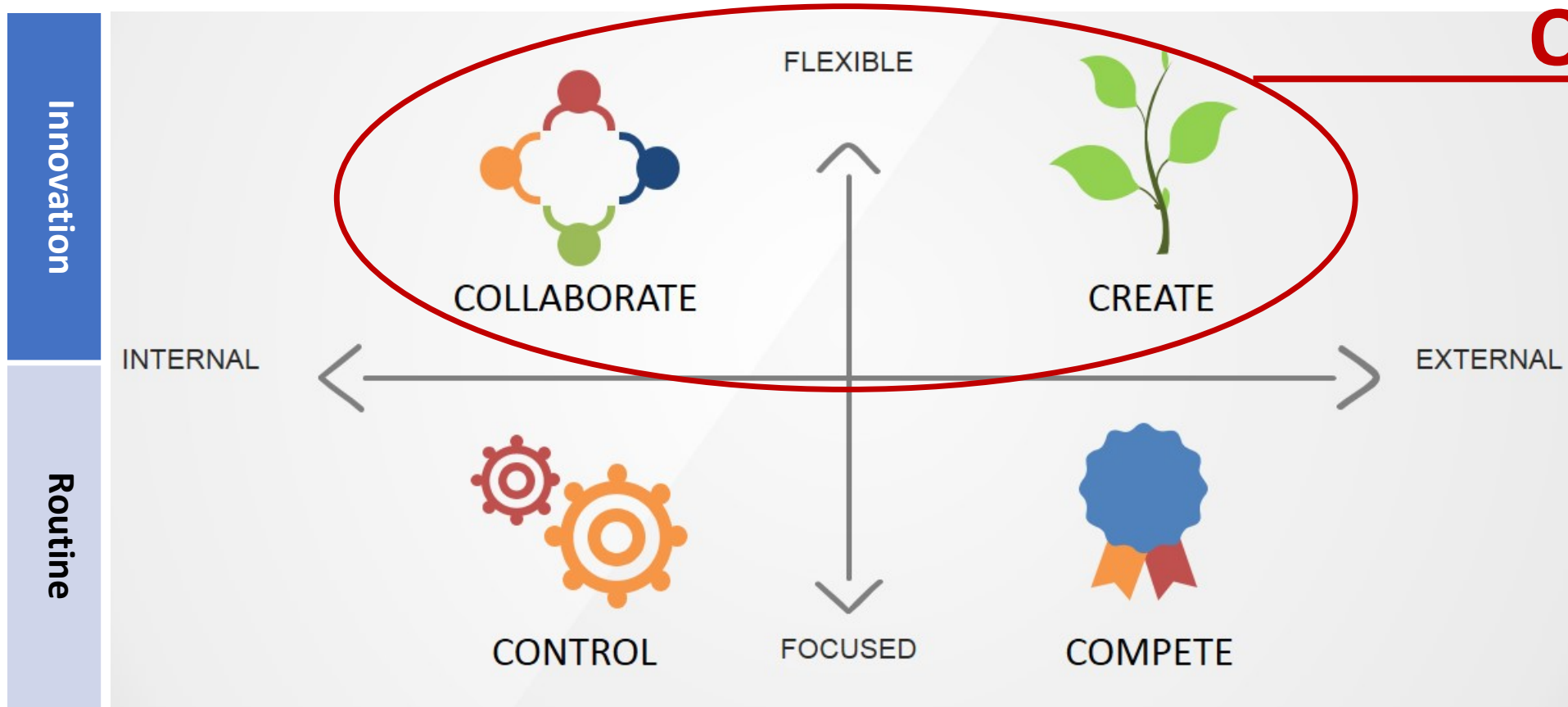


What was not mentioned in this case study ?!!



What was not mentioned in this case study ?!!

Types of Organizational Culture



Oncofertility

Organizational Culture. Competing Values Framework. Rober Quinn and John Rohrbaugh 1983.

Acknowledgement



**UNIKLINIK
KÖLN**



Thank You !!

Ovarian Tissue Freezing & Thawing (Isachenko et al)

Preparation of extracted ovarian tissue:

- Except where otherwise stated, all chemicals were obtained from Sigma (Sigma Chemical Co., St. Louis, MO, USA).
- Immediately after ovarian tissue extraction, the excised tissue is transported to our laboratory within 10 min for further processing.
- The basal medium that is used for transport and dissection is composed of Leibovitz L-15 supplemented with 5% Dextran Serum Substitute (Irvine Scientific, Santa Ana, CA, USA). The temperature of the sample will be maintained between 32°C and 34°C.
- Afterwards, ovarian cortex is dissected into small strips (medulla-containing strips: 0.5-1 x 0.5-1 cm, 1-2 mm thickness) using tweezers and scalpel No 22 under aseptic conditions.

Ovarian Tissue Freezing & Thawing (Isachenko et al)

Slow freezing protocol:

- Ovarian tissue strips are cooled at 5°C for 24 h till the next day.
- On the day of freezing, the ovarian tissue strips are placed for 30 min at room temperature in 20 ml freezing medium composed of basal medium supplemented with 6% dimethyl sulfoxide, 6% ethylene glycol and 0.15 M sucrose.
- Then each ovarian tissue strip is put into a standard 5 ml cryovial (Thermo Fisher Scientific, Rochester, NY, USA) previously filled with 4.5 ml freezing medium and frozen in a IceCube 14S freezer (SyLab, Neupurkersdorf, Austria).
- The slow cooling profile is started at -6°C, then the cryovials are cooled from -6°C to -34°C at a rate of -0.3°C/min. This slow freezing protocol includes auto-seeding step at -6°C.
- Finally at -34°C, cryovials are plunged into liquid nitrogen (-196°C) for storage.

Ovarian Tissue Freezing & Thawing (Isachenko et al)

Thawing protocol:

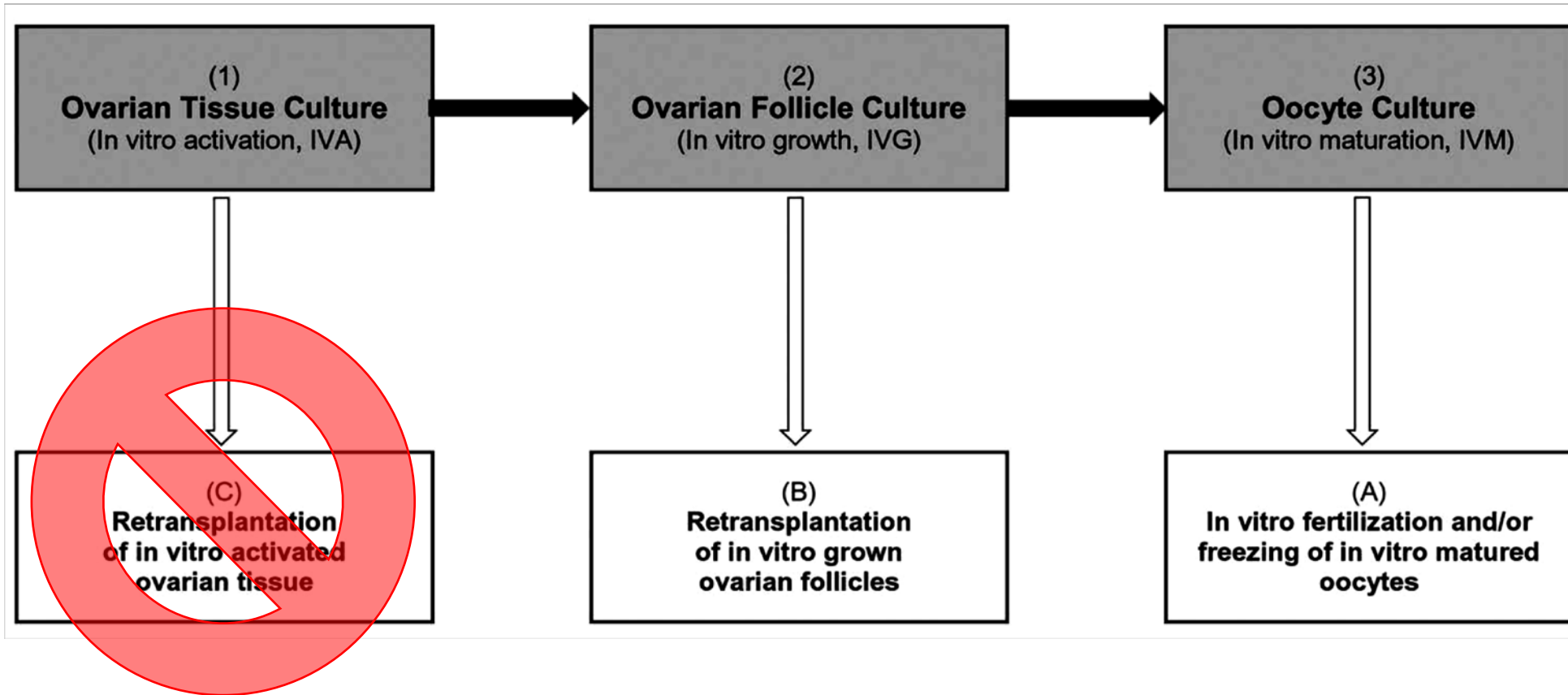
- When a pregnancy is desired, 25-50% of stored frozen ovarian tissue will be thawed out according to a rapid thawing protocol as previously described by our group.
- In order to thaw the sample, the cryovial will be removed from liquid nitrogen and held for 30 s at room temperature, then it will be immersed in a 100°C (boiling) water bath for 60 s. The exposure time in the boiling water will be visually controlled by the presence of ice in the medium. As soon as the ice will be 2 to 1 mm apex, the cryovial will be removed from the boiling water. At that point, the final temperature of the medium will be between 4°C and 10°C.
- Within 5-10 s after thawing, the ovarian tissue strip from the cryovial will be transferred to a 10 ml thawing solution (basal medium containing 0.5 M sucrose) in a 100 ml specimen container (Sarstedt, Nuembrecht, Germany). The container will be placed on a shaker and continuously agitated with 200 osc/min for 15 min at room temperature.

Ovarian Tissue Freezing & Thawing (Isachenko et al)

Thawing protocol:

- For stepwise dilution of cryoprotectants, the same 'dropping' methodology will be performed as previously described by our group.
- This will involve slow addition of basal medium to the solution of sucrose with ovarian tissue. For 'dropping', we will use 50 ml of basal medium in a 50 ml tube (Greiner Bio-One GmbH, Frickenhausen, Germany). The final sucrose concentration should result in almost isotonic conditions.
- Finally, the thawed ovarian tissue will be repeatedly washed for three times in the basal medium for 10 min.

Fertility Preservation Outcome



Artificial human ovary: the concept (grey boxes) and the applications (white boxes). (Salama et al 2017)